

Levosimendan off-label successfully used in two patients with exacerbated COPD and severe bronchospasm: a case series focusing on an explorative review of the current literature

Ludovica Golino, Marco Caiazzo, Pasquale Diglio, Espedito Tornincasa, Gianmarco Russo, Francesco Imperatore

Unit of Anesthesia and Intensive Care, San Giovanni di Dio Hospital, Frattamaggiore (NA), Italy

Abstract

Levosimendan was used off label to treat two patients with similar clinical and medical history (severe COPD, bronchospasm, cigarette smoking, difficult weaning). Starting from these two favorable cases, an explorative review of the current literature was conducted relating to this use of Levosimendan and its rationale.

Correspondence: Ludovica Golino, Unit of Anesthesia and Intensive Care, San Giovanni di Dio Hospital, Frattamaggiore (NA), Italy.
E-mail: ludovica.golino@aslnapoli2nord.it

Key words: levosimendan off-label; COPD; exacerbated COPD; case series; review.

Conflict of interest: the authors declare no potential conflict of interest, and all authors confirm accuracy.

Ethics approval and consent to participate: no ethical committee approval was required for this case report by the Department, because this article does not contain any studies with human participants or animals. Informed consent was obtained from the patient included in this study.

Patient consent for publication: the patients gave their written consent to use their personal data for the publication of this case report and any accompanying images.

Availability of data and materials: all data underlying the findings are fully available.

Received: 28 September 2023.

Accepted: 7 November 2023.

Publisher's note: all claims expressed in this article are solely those of the authors and do not necessarily represent those of their affiliated organizations, or those of the publisher, the editors and the reviewers. Any product that may be evaluated in this article or claim that may be made by its manufacturer is not guaranteed or endorsed by the publisher.

©Copyright: the Author(s), 2023

Licensee PAGEPress, Italy

Acute Care Medicine Surgery and Anesthesia 2023; 1:36

doi:10.4081/amsa.2023.36

This work is licensed under a Creative Commons Attribution-NonCommercial 4.0 International License (CC BY-NC 4.0).

Introduction

Levosimendan is a positive inotropic compound with vasodilatory properties used for the treatment of acute decompensated heart failure (AHF). The principal mechanism of levosimendan is the sensitization of troponin C to calcium in cardiac muscle, which leads to its unique feature of exerting a positive inotropic effect without increasing myocardial oxygen consumption. Furthermore, levosimendan opens adenosine triphosphate-sensitive potassium (K_{ATP}) channels in vascular smooth muscle cells and induces vasodilation of the pulmonary, coronary, and peripheral arteries and of the venous circulation. By addressing both cardiac inotropy and vascular dilatation, levosimendan improves cardiovascular coupling and cardiac mechanical efficiency. At higher doses, the drug also acts as a phosphodiesterase type 3 (PDE3) inhibitor.¹

Levosimendan is designed for the treatment of AHF in patients with low cardiac output and at high risk of surgery.² However, there are some promising and interesting off-label uses of the drug, owing to its pharmacology, as the use in patients with exacerbated chronic obstructive pulmonary disease (COPD), muscle weakness and severe bronchospasm. Treatment with the calcium-sensitizing drug levosimendan, in fact, may be effective in improving muscle function in patients with respiratory muscle weakness, which often accompanies chronic diseases such as COPD and congestive heart failure, according to researchers in the Netherlands, who studied the effects of the drug on healthy volunteers. The drug, which is normally prescribed in patients with acute heart failure, increases the sensitivity of muscle tissue to calcium, improving the muscle's ability to contract.³ Studies on animal models seem to confirm these theories.⁴ Levosimendan is generally well tolerated by patients and hypotension is one of the most observed side effects but is not common when the treatment remains within the recommended dose. If necessary, hypotension can be counteracted by low-dose norepinephrine.

Case 1

A 68-year-old female patient required orotracheal intubation, mechanical ventilation, and admitted to the ICU for severe respiratory failure caused by a COPD exacerbation (without infection). In medical history: severe COPD, smoking (40 cigarettes per day), obesity with BMI 44, arterial hypertension, type II diabetes mellitus. After six days, with a minimal improvement in respiratory exchanges on blood gas analysis, weaning was attempted with failure and further worsening of the respiratory exchanges. The P/F ratio was maintained around a value of 120. From hospitalization,

bronchodilator therapy (salbutamol 2 puffs/day) and intravenous cortisone (dexamethasone 4 mg x 2 times/day) were administered. Therefore, the patient underwent percutaneous tracheotomy and sedation was suspended with recovery of consciousness and no motor deficit. The patient remained ventilator dependent in assisted mode (pressure support 18 cmH₂O, FiO₂ 70%, PEEP 8 cmH₂O with a tidal volume of 300-400 ml, values that kept airway pressures below recommended limits). A bronchodilator therapy by aerosol was began but despite the optimization of the therapy the patient had numerous episodes (even 6-7 per day) of severe bronchospasm, which could only be resolved through adrenaline 0.1 mg in aerosol. During and after these episodes the patient desaturated with SpO₂ of 70%. Following the numerous episodes of bronchospasm that caused desaturation and maladaptation to the ventilator, the P / F steadily dropped below the value of 100. It was therefore decided to try an off-label bronchodilator therapy with Levosimendan. Echocardiography was performed before drug administration: estimated EF of 50%, TAPSE 18 mm (comparable to the previous one). Levosimendan was administered on the 15th day of hospitalization (8 days after the tracheostomy and the patient's awakening) at the following dosage: bolus of 10 mcg / kg over 10 minutes followed by an infusion of 0.1 mcg / kg / min for 24 hours. During the drug infusion no significant side effects were found, the patient always maintained good hemodynamic, the heart rate did not undergo variations above 20% of the base rate that were not justified by external causes (for example: bronchial aspiration). From the first day of starting therapy, the episodes of bronchospasm appeared drastically reduced; in the following days these episodes occurred rarely (<1 / day on average) and moreover the patient never required treatment with aerosol adrenaline. Three days after therapy with Levosimendan, a second echocardiogram was performed: estimated EF of 55%, TAPSE 18mm. The patient's muscle strength appeared to be increased as she gradually managed to reach tidal volumes of 500-600 ml with the same support pressure and without increased airway pressures. Over the next few days, blood gases gradually improved and it ventilatory support and FiO₂ were reduced. On the 20th day of hospitalization, the P / F reached the value of 200 with good adaptation to ventilation, support pressure 14 cmH₂O, PEEP 6 cmH₂O and FiO₂ 45%. On the 26th day, a P / F of 260 was reached, then the patient performed a trial of spontaneous breathing with T-tube on tracheostomy tube with FiO₂ 60%. In spontaneous breathing the P / F remained around 180 with no signs of respiratory distress. From that moment the patient alternated spontaneous breathing with P / F of about 190, with assisted ventilation with P / F about 300. After 35 days of hospitalization, the patient was discharged home without tracheostomy, and oxygen therapy during the day.

Case 2

A 62-year-old female patient required orotracheal intubation, mechanical ventilation, and admitted to the ICU for severe respiratory failure caused by a COPD exacerbation (without infection). In medical history: emphysematous COPD, smoking (50 cigarettes per day), malnutrition with BMI 17, arterial hypertension. After seven days, with a minimal improvement in respiratory exchanges on blood gas analysis, weaning was attempted with failure and further worsening of the respiratory exchanges. The P/F ratio was maintained around a value of 100. From hospitalization, bronchodilator therapy (salbutamol 2 puffs/day) and intravenous cortisone (dexamethasone 4 mg x 2 times/day) were administered. Therefore, the patient underwent percutaneous tracheotomy and sedation was suspended with recovery of consciousness and no motor deficit. The patient remained ventilator dependent in assisted mode (pressure

support 14 cmH₂O, FiO₂ 60%, PEEP 6 cmH₂O with a tidal volume of 200-300 ml, values that kept airway pressures below recommended limits). A bronchodilator therapy by aerosol was began but despite the optimization of the therapy the patient had numerous episodes (even 4-5 per day) of severe bronchospasm, which could only be resolved through adrenaline 0.1 mg in aerosol. During and after these episodes the patient desaturated with SpO₂ of 80%. It was therefore decided to try an off-label bronchodilator therapy with levosimendan. Echocardiography was performed before drug administration: estimated EF of 60%, TAPSE 19 mm. Levosimendan was administered on the 12th day of hospitalization (6 days after the tracheostomy and the patient's awakening) at the following dosage: bolus of 10 mcg / kg over 10 minutes followed by an infusion of 0.1 mcg / kg / min for 24 hours. During the drug infusion no significant side effects were found. Three days after therapy with Levosimendan, a second echocardiogram was performed: estimated EF of 60%, TAPSE 19 mm (comparable to the previous one). From the first day of starting therapy, the episodes of bronchospasm appeared drastically reduced; in the following days these episodes occurred rarely (<1 / day on average) and moreover the patient never required treatment with aerosol adrenaline. The patient's muscle strength appeared to be increased as she gradually managed to reach tidal volumes of about 400 ml with the same support pressure and without increased airway pressures. Over the next few days, blood gases gradually improved and it ventilatory support and FiO₂ were reduced. On the 20th day of hospitalization, the P / F reached the value of 200 with good adaptation to ventilation, support pressure 12 cmH₂O, PEEP 5 cmH₂O and FiO₂ 35%. On the 20th day, a P / F of 300 was reached, then the patient performed a trial of spontaneous breathing with T-tube on tracheostomy tube with FiO₂ 40%. In spontaneous breathing the P / F remained around 250 with no signs of respiratory distress. From that moment the patient alternated spontaneous breathing with P / F of about 250, with assisted ventilation with P / F greater than 300. After 25 days of hospitalization, the patient was discharged home without tracheostomy and oxygen therapy during the day.

Materials and Methods

To identify utility of Levosimendan in COPD we conducted a non-systematic literature research.

A literature searches up to September 2023 in PUBMED was performed using the following research terms: "Levosimendan in COPD, Levosimendan off-label, Levosimendan in bronchospasm."

Publications were accepted in any format, language, or publication status. All retrospective, prospective and randomized controlled studies, case reports and case series on humans and animal studies were included. Studies on pediatric population were excluded. The initial research identified 19 studies. A total of 13 studies were excluded: 4 studies concerned pediatric patients, the other 9 did not focus on the research topic. Publications included in the review were 6 (Figure 1). We list all the studies included in the review in chronological order of publication; we also specified the study type (Table 1).

Results

The use of levosimendan appeared effective in two clinical cases. Patients selected for off-label therapy were both characterized by exacerbated COPD, cigarette smoking, numerous episodes of bronchospasm, difficult weaning expected. In both cases, levosimendan therapy was related to an increase in P/F following a greater

adaptation to the mechanical ventilator, a drastic reduction in bronchospasm episodes, the absence of significant side effects. Chronic obstructive pulmonary disease (COPD) is a chronic inflammatory disorder of the lung characterized by poorly reversible airflow limi-

tation. There is also an important muscle weakness which can disadvantage weaning from mechanical ventilator. It is not a unique disease entity but rather a complex of conditions which include emphysema, chronic bronchitis and, sometimes coexists with asthma.

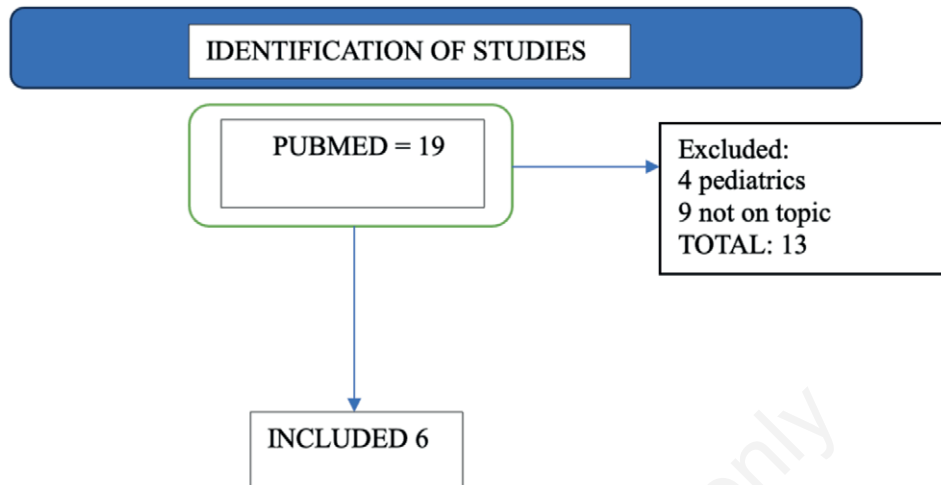


Figure 1. Review flowchart.

Table 1. Publications included in the explorative review.

Author	Title	Year of publication	Type of study	Conclusions
Van Hees <i>et al.</i> ⁵	Levosimendan enhances force generation of diaphragm muscle from patients with chronic obstructive pulmonary disease	2009	Research Control Trial	Levosimendan enhances force generating capacity of diaphragm fibers from patients with and without COPD patients by increasing calcium sensitivity of force generation. These results provide a strong rationale for testing the effect of calcium sensitizers on respiratory muscle dysfunction in patients with COPD
Ouanes-Besbes <i>et al.</i> ⁷	Weaning difficult-to-wean chronic obstructive pulmonary disease patients: a pilot study comparing initial hemodynamic effects of levosimendan and dobutamine	2011	Comparative study	Both drugs reduced the magnitude of pulmonary artery occlusion pressure (PAOP) increase at spontaneous breathing in difficult-to-wean COPD patients. PAOP increase was reduced to a greater extent by Levosimendan
Doorduyn <i>et al.</i> ⁸	The calcium sensitizer levosimendan improves human diaphragm function	2012	Randomized control trial	The calcium sensitizer levosimendan improves neuromechanical efficiency and contractile function of the human diaphragm. These findings suggest a new therapeutic approach to improve respiratory muscle function in patients with respiratory failure
Brussels <i>et al.</i>	Ventilator-induced diaphragm dysfunction: clinically relevant problem ⁹	2014	English abstract German review	Levosimendan has been proven to increase diaphragm contractile forces in humans which may prove to be helpful for patients experiencing difficult weaning
Babik <i>et al.</i>	Levosimendan prevents bronchoconstriction and adverse respiratory tissue mechanical changes in rabbits ⁴	2017	Research controlled trial	The beneficial effects of Levosimendan on the lung periphery were also reflected in its ability to prevent elevations in respiratory tissue damping and stiffness. The association of these well-known circulatory effects with the currently demonstrated beneficial changes in respiratory mechanics might decrease the oxygen demand of spontaneous breathing. This multimodal cardiorespiratory benefit has a potential of shortening the time of invasive ventilation following its application
Zambelli <i>et al.</i>	Treatment with levosimendan in an experimental model of early ventilator-induced diaphragmatic dysfunction ⁶	2023	Research controlled trial	Levosimendan preserves muscular cell structure (cross-sectional area) and muscle autophagy after 5 hours of mechanical ventilation in a rat model. However, Levosimendan did not improve diaphragm contractile efficiency

Levosimendan could be a useful therapeutic tool to overcome a COPD exacerbation, due to its bronchodilator effect (COPD with asthmatic component) and ability to stimulate muscle fibers (respiratory pump deficiency in severe COPD).

Already in 2009, an experimental study was conducted by van Hees et al. injecting predefined amounts of Levosimendan onto diaphragm muscle fibers of volunteers (COPD and non-COPD).⁵ The study demonstrated that Levosimendan enhances the force-generating capacity of diaphragm fibers from patients with and without COPD by increasing calcium sensitivity of force generation. In a much more recent trial mouse models were used, and the available data demonstrated that the infusion of levosimendan prevents muscle damage related to mechanical ventilation in mice, although it does not appear to influence muscle contractility.⁶

Our series of two patients and the material found in the literature seem to constitute data in favor of levosimendan in patients with acute COPD and bronchospasm.

Conclusions

In conclusion, the use of Levosimendan in patients with COPD, bronchospasm and expected difficult weaning due to muscle pump deficiency is an interesting possibility. The literature offers some ideas, but it is an area that requires further study and in-depth analysis.

References

1. Nieminen MS, Fruhwald S, Heunks LM, et al. Levosimendan: current data, clinical use and future development. *Heart Lung Vessel* 2013;5:227-45.
2. Pienkowski P, Voors AA, Anker SD, et al. ESC Scientific Document Group. 2016 ESC Guidelines for the diagnosis and treatment of acute and chronic heart failure: the Task Force for the diagnosis and treatment of acute and chronic heart failure of the European Society of Cardiology (ESC). Developed with the special contribution of the Heart Failure Association (HFA) of the ESC. *Eur Heart J*. 2016;37:2129-2200.
3. American Thoracic Society. Heart drug offers possible treatment for patients facing respiratory failure. *ScienceDaily* 2011. Available from: <https://www.sciencedaily.com/releases/2011/09/110923095806.htm>
4. Babik B, Balogh AL, Sudy R, et al. Levosimendan prevents bronchoconstriction and adverse respiratory tissue mechanical changes in rabbits. *Am J Physiol Lung Cell Mol Physiol* 2017;313:L950-L956.
5. Van Hees HW, Dekhuijzen PN, Heunks LM. Levosimendan enhances force generation of diaphragm muscle from patients with chronic obstructive pulmonary disease. *Am J Respir Crit Care Med* 2009;179:41-7.
6. Zambelli V, Murphy EJ, Delvecchio P, et al. Treatment with levosimendan in an experimental model of early ventilator-induced diaphragmatic dysfunction. *Drug Target Insights* 2023;17:39-44.
7. Ouanes-Besbes L, Ouanes I, Dachraoui F, et al. Weaning difficult-to-wean chronic obstructive pulmonary disease patients: a pilot study comparing initial hemodynamic effects of levosimendan and dobutamine. *J Crit Care* 2011;26:15-21.
8. Doorduyn J, Sinderby CA, Beck J, et al. The calcium sensitizer levosimendan improves human diaphragm function. *Am J Respir Crit Care Med* 2012;185:90-5.
9. Bruells CS, Marx G, Rossaint R. Ventilatorinduzierte diaphragmale Dysfunktion: Klinisch relevantes Problem [Ventilator-induced diaphragm dysfunction : clinically relevant problem]. *Anaesthesist* 2014;63:47-53.